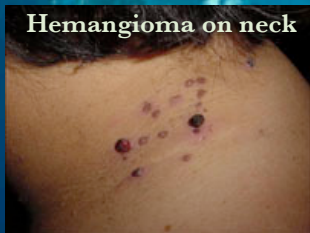

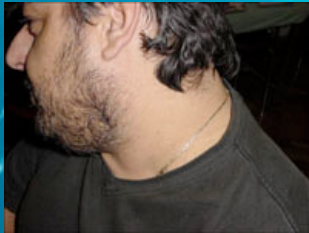CRYO-SURGERY

D R . R O D S A N T O S

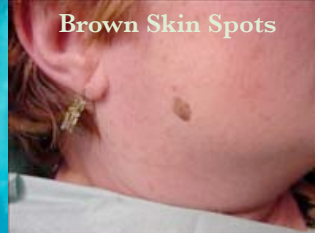

Hemangioma on neck

Before

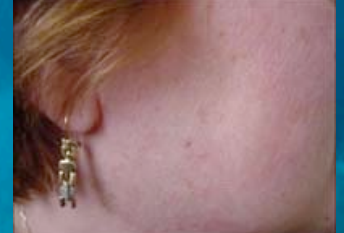

4 Weeks after



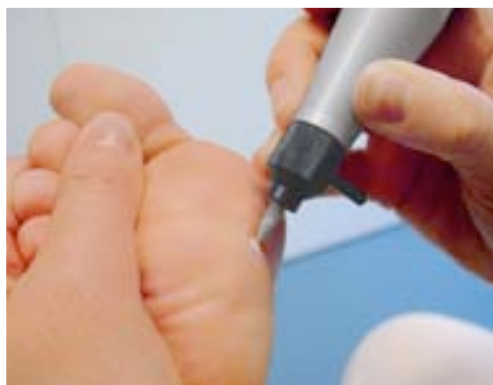Brown Skin Spots

Before



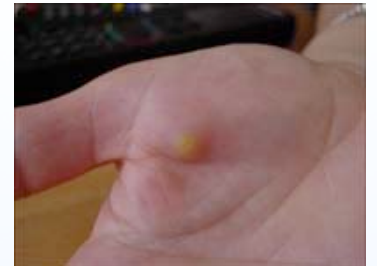4 Weeks after

The removal of cosmetic irregularities is becoming increasingly common as we all desire to be good looking and stay attractive as we age. Dr. Santos utilizes the newest technology in cryosurgery that offers unparalleled freezing power combined with total accuracy minimizing side effects and generating results! It only takes 1 or 2 treatments to remove the skin lesion.

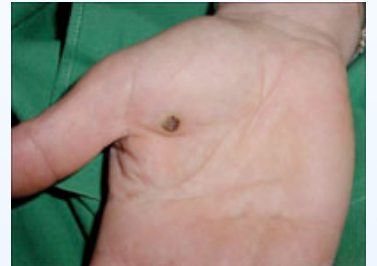

Remove your skin lesions today! Book an appointment for a free consultation.

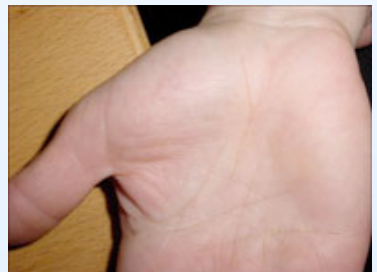
Wart on hand



Before



8 day post treatment

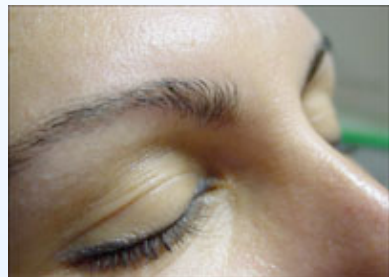
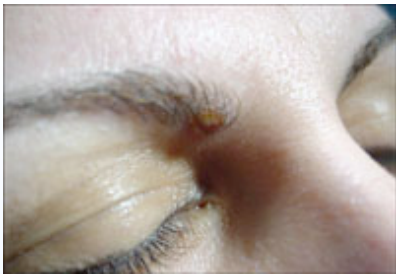
4 Weeks post treatment

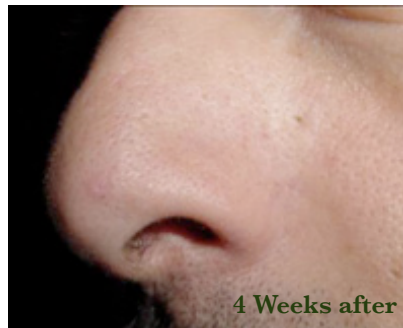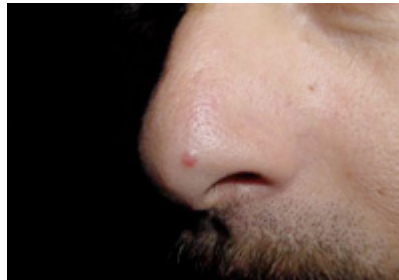CRYOSUGERY

NOSE LESION

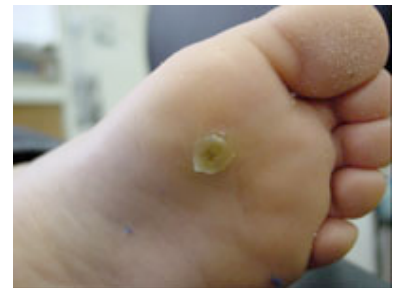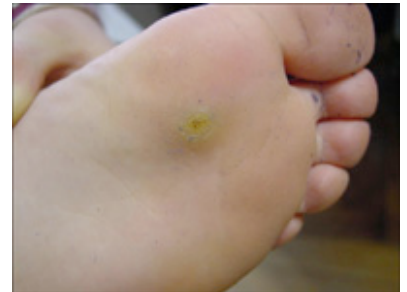PLANTAR WART



Lesion on eyebrow - 4 weeks after treatment the lesion is gone and the hair follicle remains

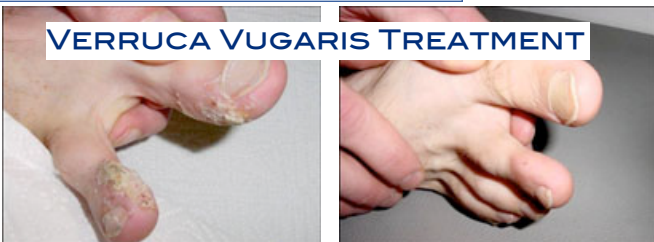

4 Weeks after



4 Weeks after

VERRUCA VUGARIS TREATMENT



SKIN CONDITIONS TREATED

Acne Vulgaris	Granuloma faciale	Myxoid Cust	Warts
Adenoma	Hemangioma	Moles	Skin Tags
Angiolymploid Hyperplasia	Keloid	Basal Cell Carcinoma	Chondrodermatitis nodularis
Angiokeratoma	Keratosis seborrhoic & actinic	Seborrhheic keratosis	Lentigines
Cherry Angioma	Mulluscum contagiosum	Verruca vulgaris	